



*STATE OF THE ART*

## **Phosphorus necrosis of the jaw: a review of an 19<sup>th</sup> and early 20<sup>th</sup> centuries occupational disease**

Vanessa Campanacho

American Museum of Natural History, USA

CIAS – Research Centre for Anthropology and Health, University of Coimbra, Portugal

CFE - Centre for Functional Ecology - Science for People & the Planet, Forensic Anthropology and Paleobiology, University of Coimbra, Portugal

Corresponding author: [vcampanacho@gmail.com](mailto:vcampanacho@gmail.com)

Article received on the 22<sup>nd</sup> of June of 2020 and accepted on the 9<sup>th</sup> of October of 2020

---

### ABSTRACT

In the 19<sup>th</sup> century, easy ignitable matches were a technological advancement but the white phosphorus component led to a new industrial disease, the phosphorus necrosis of the jaw. This paper draws awareness to phosphorus necrosis of the jaw as only a few archaeological cases have been reported in the literature. Phosphorus necrosis of the jaw affected mostly women and children exposed to white phosphorus fumes in poorly ventilated factories. Phosphorus necrosis of the jaw started with a dull pain, as the disease progressed, bone necrosis and an *involutrum* would form. Sometimes this disease could be fatal, but if the individual survived could be socially stigmatized due to facial disfigurement and foul smell. Treatments involved mouth-washes and surgical extraction of necrotic bone. Other pathological conditions can cause osteomyelitis in the

jaw. Besides a paleopathological analysis, the archaeological context and a calculus analysis for phosphorus levels should be taken into consideration to aid in the differential diagnosis.

*Keywords: industrial disease; osteomyelitis; phossy jaw; osteonecrosis of the jaw.*

\*\*\*

## RESUMO

No século XIX, os palitos de fósforos foram considerados um avanço tecnológico, mas o componente fósforo branco levou à emergência de uma nova doença industrial, a necrose fosforosa da mandíbula. O presente artigo alerta para, e descreve, quais os sintomas da necrose fosforosa da mandíbula, visto que poucos casos arqueológicos foram mencionados na literatura. A necrose fosforosa da mandíbula afectou nomeadamente mulheres e crianças expostas a fumos tóxicos em fábricas com uma ventilação deficiente. Geralmente, a necrose fosforosa começava com dor localizada que, com o tempo, resultava em osteomielite. Esta doença podia ser fatal, mas aqueles que sobreviveram, por vezes sofriam de estigma social associado ao desfiguramento facial e pestilento odor. Elixires para a lavagem da boca e cirurgia para remoção de osso necrótico foram os tratamentos recomendados na época. Outras doenças também podem resultar em osteomielite na mandíbula e maxila. Por isso, para além da análise patológica, o contexto arqueológico e análise do nível de fósforo presente no cálculo dentário devem ser factores em conta durante o diagnóstico diferencial.

*Palavras-chave: doença industrial; osteomielite; mandíbula de fósforo; necrose fosforosa da mandíbula.*

**P**hosphorus necrosis of the jaw - also known as 'phossy jaw' and osteonecrosis of the jaw - was an industrial disease mostly associated with white phosphorus matches production in the 19<sup>th</sup> and early 20<sup>th</sup> centuries. It mostly affected young women and children, although it also affected young men working in close contact with the toxic fumes ([Hinshaw and Quinn, 2005](#); [Pollock et al., 2015](#); [Roberts et al., 2016](#)). Reports relayed

that phosphorus necrosis of the jaw could happen after three to five years of exposure to white phosphorus, also called yellow phosphorus ([Pollock et al., 2015](#)). A mortality rate of 20% was reported for this disease before antibiotics emergence ([Hughes et al., 1962](#); [Myers and McGlothlin, 1996](#)). However, those that survived this painful and debilitating disease suffered social stigma due to facial disfigurement and purulent smell from the foul discharge on the mouth

([Roberts et al., 2016](#)). The first case of phosphorus necrosis of the jaw emerged in Vienna (Austria) in 1838, seven years after white phosphorus match industry establishment in this country ([Harrison, 1996](#)). Other countries followed in reporting the emergence of phosphorus necrosis ([Hughes et al., 1962](#)).

Ignitable matches were commonly called 'lucifers' or 'congreves' ([Arnold, 2004](#)). In the 19<sup>th</sup> century, twenty percent white phosphorus coatings were added to the sulfur-based friction match-sticks for a quicker ignition ([Hughes et al., 1962](#); [Jacobsen et al., 2014](#); [Pollock et al., 2015](#)). A French chemist, Dr. Charles Sauria, is pointed as the possible creator behind coating ignitable matches with white phosphorus in 1830 without patenting it ([Marx, 2008](#); [Lehman, 2017](#)). White phosphorus matches were quickly spread into different countries establishing an international matchmaking industry (Marx, 2008). Initially, the match industry was mostly performed in the workers' cottage homes, but with time expanded to factories, with the first match factory opening in Vienna ([Hughes et al., 1962](#); [Lehman, 2017](#)).

For the match production, splints of wood - twice the length of a match - were heat-dried before being dipped into sulphur or paraffin ([von Bibra and Geist, 1848](#); [Roberts et al., 2016](#); [Lehman, 2017](#)). The splints of wood were then put into a frame and dipped into a mixture of white phosphorus, chlorate of potash, coloring substance, and glue on both extremities ([von Bibra and Geist, 1848](#); [Roberts et al., 2016](#); [Lehman, 2017](#)). The frame with matches would then be put to dry between 27 °C and 32 °C ([von Bibra and](#)

[Geist, 1848](#)). After dried, the splints of wood would be removed from the frame, cut in the middle, counted and boxed as shown in [Figure 1](#) ([von Bibra and Geist, 1848](#); [Roberts et al., 2016](#); [Lehman, 2017](#)).



**Figure 1 - Women cutting and boxing matches in a match factory in London, 1871. Public domain.**

Shifts at the match factories entailed long hours in dangerous, unclean, and poorly ventilated conditions ([Arnold, 2004](#); [Roberts et al., 2016](#); [Lehmann, 2017](#)). Match workers were uneducated and young individuals from the poorest sector of the population ([Lehmann, 2017](#)), and employment of women and children ensured low wages ([Roberts et al., 2016](#)). Wages were also dependent on the worker's speed to perform certain tasks ([Arnold, 2004](#)). In some cases, as the Bryant and May's matching factory, wages were also reliant on an abusive punishing system of fines ([Harrison, 1996](#); [Arnold, 2004](#)). The fines consisted of monetary deductions for what employers and managers considered transgressive

behavior such as being late, uncleanliness, mistakes, talking, going to the restroom without authorization, and damage to the merchandise ([Harrison, 1996](#); [Arnold, 2004](#)).

Workers also had to pay for the materials used during match production ([Arnold, 2004](#)). The fine system ensured the lack of wages, as some were working to pay the debt incurred by the fines they suffered ([Harrison, 1996](#)). Match production was usually based on gendered tasks since the dipping and drying of the matches were usually performed by men and young boys, but the cutting and boxing were often done by young girls and women ([Lehmann, 2017](#)). Although women were not directly exposed to the fumes during the white phosphorus coating and drying process, they were still at risk of developing phosphorus necrosis of the jaw ([Harrison, 1996](#); [Roberts et al., 2016](#); [Lehmann, 2017](#)). On poorly ventilated factories the fumes produced on the dipping and drying areas would be carried to other areas, especially if those activities occurred on the lower level while cutting and boxing occurred on the superior level ([Harrison, 1996](#); [Arnold, 2004](#); [Lehmann, 2017](#)).

Other risks women and young girls could suffer were the spontaneous ignition of the matches while boxing them, which would release toxic fumes ([Harrison, 1996](#)). Due to fumes produced throughout the white phosphorus coating process the factory walls and furniture were luminescent at night ([Roberts et al., 2016](#)). Workers also showed the same greenish-white glow on their hands, breath, and clothes, and on damaged areas of the jaw in the dark ([Roberts et al., 2016](#)).

With phosphorus necrosis of the jaw emergence in match-making factories, it was

considered a dangerous trade and regulations to prevent new cases were imposed such as washing hands with alkaline soda water; work-environment cleanliness; ventilation; separate rooms for different stages of the match-making process; notifying authorities for new cases of phosphorus necrosis of the jaw; limit the amount of white phosphorus coating to 10%; and regular dental and medical inspection ([Ward, 1926](#); [Harrison, 1996](#); [Lehmann, 2017](#)). Although these regulations diminished the number of phosphorus necrosis of the jaw it did not eradicate the disease as new cases continued to emerge ([Ward, 1926](#); [Arnold, 2004](#)). To avoid further scrutiny from the authorities some factories - as Bryant and May's - tried to conceal the rise of new cases of phosphorus necrosis of the jaw by sending the workers home with monetary compensation and the threat that they could only seek the company's doctor ([Harrison, 1996](#); [Arnold, 2004](#); [Marx, 2008](#); [Lehmann, 2017](#)).

Any deaths resulting from phosphorus necrosis were also covered up ([Arnold, 2004](#)). However, this concealment was found out by the press bringing the public a greater awareness for white phosphorus matches as a health hazard and more governmental investigations ([Harrison, 1996](#); [Lehmann, 2017](#)). A safer non-toxic alternative to white phosphorus matches emerged in the 1850s in Sweden, composed by antimony sulfide and potassium chlorate on its head which would be ignited by striking it on amorphous red phosphorus surface ([Myers and McGlothlin, 1996](#); [Arnold, 2004](#); [Marx, 2008](#)). But red phosphorus matches implementation happened later as it had a less

straightforward ignition compared to the white phosphorus matches ([Marx, 2008](#); [Lehmann, 2017](#)).

The first country to ban white phosphorus coated matches was Finland in 1872 ([Hughes et al., 1962](#); [Myers and McGlothlin, 1996](#); [Marx, 2008](#)). Other European countries followed suit on banning white phosphorus matches in the 1906 International Treaty of Berne in Switzerland ([Ward, 1926](#); [Hughes et al., 1962](#); [Myers and McGlothlin, 1996](#); [Marx, 2008](#); [Jacobsen et al., 2014](#); [Lehmann, 2017](#)). In 1925, almost all world countries signed the International Treaty of Berne ([Ward, 1926](#)).

Other industries also employed white phosphorus to make fireworks, phosphor-bronze, brass founders, war ammunitions, fertilizer, a phosphorus compound, and pest control poisons ([Ward, 1926](#); [Hughes et al., 1962](#); [Hellstein and Marek, 2005](#); [Roberts et al., 2016](#)). In these industries, occasional cases of phosphorus necrosis of the jaw were recorded ([Ward, 1926](#); [Hughes et al., 1962](#)). Sporadic cases of phosphorus poisoning outside of the industrial environment also occurred. von Bibra and Geist ([1848](#)) described a case of a seven years-old girl with phosphorus necrosis of the jaw from constantly lighting Lucifer matches for her amusement.

Phosphorus poisoning in children consuming fireworks resembling a candy lozenge was also described ([Ward, 1926](#)). White phosphorus as a treatment for rickets in the 19<sup>th</sup> and 20<sup>th</sup> centuries could potentially lead to phosphorus necrosis of the jaw ([Roberts et al., 2016](#)). Twenty-first-century cases of osteonecrosis of the jaw have likewise been reported due to the oral and intravenous administration of

medications based on bisphosphonate to suppress bone turnover for diseases such as osteoporosis, malignant neoplasms and Paget's disease ([Robinson and Yeo, 2004](#); [Fresco et al., 2006](#); [Phal et al., 2007](#); [Borromeo et al., 2011](#); [Gavrić et al., 2014](#)).

This article will describe phosphorus necrosis of the jaw, including its possible etiology and treatment as an industrial disease in the 19<sup>th</sup> and 20<sup>th</sup> centuries. Few archaeological cases of phosphorus necrosis of the jaw have been reported up to this date; this article aims to bring awareness to this disease, especially to researchers studying industrial communities from the 19<sup>th</sup> and early 20<sup>th</sup> centuries which may have had contact with white phosphorus.

### **Phosphorus necrosis of the jaw in the 19th and 20th centuries**

Phosphorus necrosis of the jaw was a debilitating disease which could affect both the maxilla and mandible, even though it affected the mandible more often ([von Bibra and Geist, 1848](#); [Hellstein and Marek, 2005](#); [Marx, 2008](#); [Roberts et al., 2016](#)). This disease started as an intermittent pain usually perceived as a toothache, especially as a dull red area emerged in proximity to a diseased tooth ([Wood, 1857](#); [Hellstein and Marek, 2005](#); [Marx, 2008](#)). The face would become swollen ([Wood, 1857](#); [Hughes et al., 1962](#)). Gums would also be inflamed with tenderness and darkened ([von Bibra and Geist, 1848](#); [Harrison, 1996](#)). The pain would then become constant and severe, even extending from the jaw to the throat, cheeks, ears, and head ([Wright, 1846-1847](#); [von Bibra and Geist, 1848](#); [Harrison, 1996](#)). Fever was

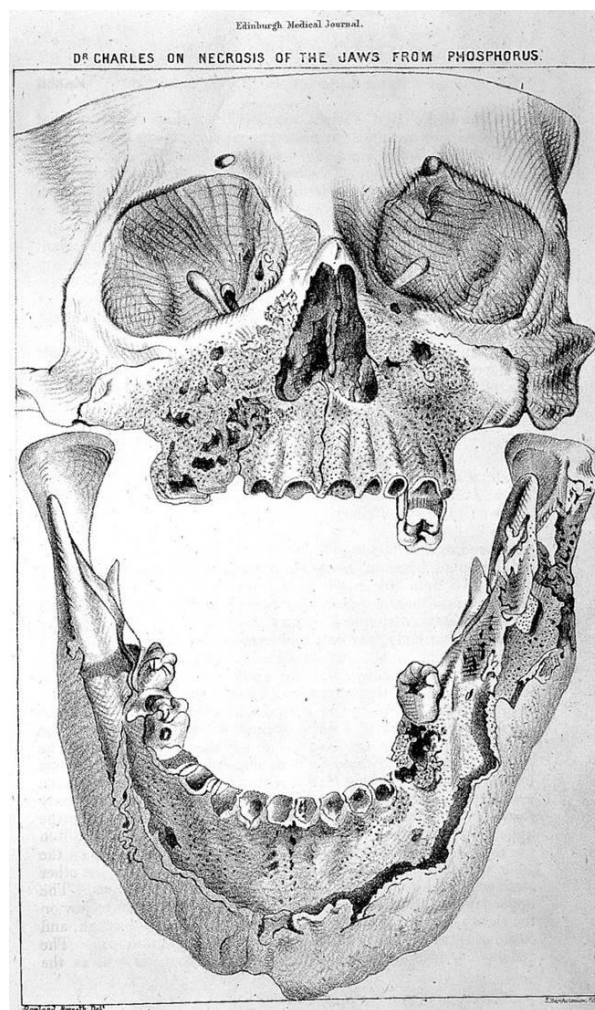


also reported in some cases ([von Bibra and Geist, 1848](#); [Ward, 1926](#)).

When diagnosed as a toothache, usually the course of action was to extract the carious tooth ([Wood, 1857](#); [Hellstein and Marek, 2005](#)). However, the tooth extraction did not improve the diagnostic, as the pain and swelling would still be a constant ([Harrison, 1996](#)). Additionally, the socket would not heal, which could even discharge pus ([Hellstein and Marek, 2005](#)). The gums would retract from the alveolar surface, which loosened the teeth and even lead to tooth loss ([Wright, 1846-1847](#); [von Bibra and Geist, 1848](#)). On the bone, severe osteomyelitis of the jaw would be formed with bone sequestration associated with irregular osteolytic lesions and involucrum, as shown in [Figure 2](#) ([Ward, 1926](#); [Hellstein and Marek, 2005](#); [Roberts et al., 2016](#)). The necrotic bone was reported to be porous, light-weighted, rough, with a brownish-black color and a pumice stone appearance ([Marx, 2008](#)).

As the disease progressed, the necrotic bone would be exposed, although it would not show the entirety of the lesion ([Jacobsen et al., 2014](#)). Woven bone and partly remodeled lamellar bone could be present at the jaw ([Roberts et al., 2016](#)), and medullary bone could also show sclerotic bone ([Hellstein and Marek, 2005](#)). In cases presenting osteomyelitis, pus and necrotic tissue could be expelled through sinus tracts onto the skin surface ([Wood, 1857](#); [Jacobsen et al., 2014](#)). With disease progression, the individual would present difficulty to masticate solid food, leading to frailty ([Wood, 1857](#); [Marx, 2008](#)). The odorous discharge associated to facial disfigurement ([Figure 3](#))

could potentially lead to social stigma, and struggle to find a new source of employment ([Wood, 1857](#); [Roberts et al., 2016](#)) The spread of the infection could lead to meningitis, septicemia, and even death ([Jacobsen et al., 2014](#); [Roberts et al., 2016](#)).



**Figure 2 - Phosphorus necrosis of the jaw (Credit: Skull with jaw affected by phosphorus poisoning. Credit: Wellcome Collection. Attribution 4.0 International (CC BY 4.0)).**

It is also possible that postcranial changes could also have occurred with white phosphorus inhalation in poorly ventilated rooms. Deardean ([1899](#)) also reported the

fracture of long bones, especially of the femur among a few workers of the white phosphorus matches' industry; in some cases, the trauma happened more than once in the same location. It is possible that the extended contact with white phosphorus may have altered the bone tissue composition making it fragile to external forces ([Deardean, 1899](#)). Some individuals showing frequent trauma on the long bones also had phosphorus necrosis of the jaw ([Deardean, 1899](#)).

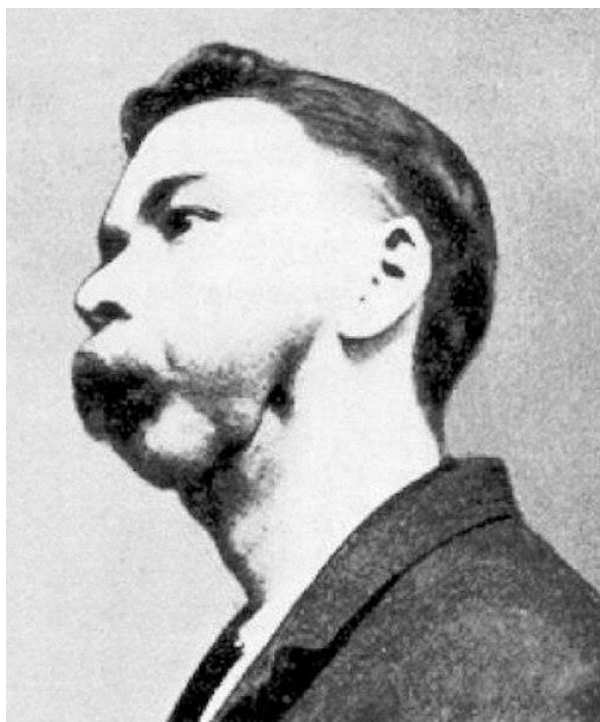


Figure 3 - Facial disfigurement in a match worker with phosphorus necrosis of the jaw. Public domain.

Animal testing in the 19<sup>th</sup> century revealed that white phosphorus is behind osteonecrosis of the jaw ([von Bibra and Geist, 1848](#); [Wood, 1857](#); [Jacobsen et al., 2014](#)). However, the physiologic mechanism of how it happens is poorly understood

([Hellstein and Marek, 2005](#)). The most popular explanation is that it is a localized disease within decayed teeth which allowed phosphorus fumes to have contact with periosteum and bone ([Wood, 1857](#); [Jacobsen et al., 2014](#)). Therefore, dental health was considered to potentially predispose for the development of phosphorus necrosis of the jaw ([Harrison, 1996](#); [Jacobsen et al., 2014](#)) but cases of phosphorus poisoning were also reported for individuals without dental problems ([Roberts et al., 2016](#)). This disease may be systemic instead - with phosphorus entering the bloodstream through ingestion and inhalation - since it also affects postcranial elements and delays development even after individuals are no longer in contact with white phosphorus ([Hughes et al., 1962](#)).

#### Archaeological cases of phosphorus necrosis of the jaw

To date, only two archaeological cases of phosphorus necrosis of the jaw have been published. Roberts *et al.* ([2016](#)) reported a case of potential phosphorus necrosis on the skeleton of an individual aged 12-14 years old buried at North Shields (England) in the 18<sup>th</sup>-19<sup>th</sup> century. This individual had woven bone and lamellar bone associated with osteolytic lesions present on the visceral surface of ribs. Poorly ventilated conditions on matches' factories and the high inhalation of toxic fumes by the workers during production could also have led to the pulmonary inflammation. Even though, other possibilities such as tuberculosis or neoplastic disease could also result in lesions on the ribs. Therefore, a careful association between

lesions in the ribs with the inhalation of toxic fumes during matches' production should be made with caution.

Another archaeological case of a young male from 19<sup>th</sup> century Gloucester (UK) with phosphorus necrosis of the jaw was reported by Valoriani *et al.* (2020). The left mandible presented bone necrosis associated to an *involutum*. An osteolytic lesion on the left ascending ramus was also recorded. Valoriani *et al.* (2020) suggested the individual was a "dipper" in a match factory due to the strong muscle insertions on the upper limbs, indicating a repetitive movement and biomechanical stress on this element.

### Treatments for phosphorus necrosis of the jaw

Non-invasive and invasive treatments for phosphorus necrosis were prescribed before the emergence of antibiotics. Tonics and gargles, such as a solution of potash, niter mixture, iodine, chlorides, myrrh, and flaxseed poultice were administered (von Bibra and Geist, 1848; Wood, 1857). Morphine was given to ease pain too (Ward, 1926). Exercise, nourishing diet, fresh air, and leeches were recommended as well (von Bibra and Geist, 1848; Wood, 1857; Ward, 1926). To ease swelled areas and gums inflammation sometimes incisions would be performed to drain pus (Wood, 1857; Ward, 1926). In 1850, two surgery approaches were advocated (Jacobsen *et al.*, 2014). A more invasive strategy implicated an early removal of necrotic bone and surrounding healthy bone to halt its spreading (Jacobsen *et al.*, 2014). The conservative approach advocated minimal surgery to remove the sequestrum

in an attempt to preserve the periosteum so bone could regenerate (Jacobsen *et al.*, 2014). The extraction of necrotic bone could be performed in multiple surgical procedures and the mandible could even be entirely removed (Ward, 1926; Wood, 1857). Depending on bone's fragility, it could even be removed through blunt force without the aid of surgical instruments (Marx, 2008). While analyzing skeletons of individuals who suffered phosphorus necrosis of the jaw, possible cut marks and/or evidence of blunt force trauma should be recorded as it may have been originated from surgical procedures.

### Differential diagnosis

Other diseases may produce modifications similar to phosphorus necrosis of the jaw, such as osteomyelitis secondary to dental diseases (Campillo, 2001; Ortner, 2003), and trauma to the jaws (Gudmundsson *et al.*, 2017). Therefore, a detailed analysis of oral diseases is important, although workers from the matches' factory may also have decayed oral health which may be a point of entrance for phosphorus poisoning.

Another industrial disease which can be mistaken with phosphorus necrosis of the jaw is osteoradionecrosis, also known as "radium jaw" and radium-induced osteomyelitis of the jaw. Osteoradionecrosis emerged in the 1920s in women painting luminous watch dials and airplane instruments with radium (Evans, 1933). As the watch dials were of reduced size the workers tipped the brush with their mouths for better results (Evans, 1933; Martland,



[1931](#)). Such behavior resulted in a daily ingestion of radium with 4000 µg of radium estimated to be the normal amount consumed in six months ([Gunderman and Gonda, 2015](#)). Victims of radium poisoning could suffer from necrosis of the jaw, however not all developed it ([Martland, 1931](#)). Besides, anemia, osteitis, osteosarcomas, and leukemia could arise in radium poisoning ([Evans, 1933](#); [Martland, 1931](#)). Osteitis and osteosarcomas could emerge in different skeletal elements, such as the femur, pelvis, cranium, mandible, humerus, scapula, and foot, which could also suffer secondary fractures ([Martland, 1931](#); [Evans, 1933](#)). However, different types of neoplasms can produce similar lesions on the jaw too ([Eldaya et al., 2017](#); [Neha and Mahajan, 2018](#); [Valoriani et al., 2020](#)).

Tuberculous osteomyelitis is a rare condition secondary to pulmonary tuberculosis ([Kamath et al., 2015](#); [Tellez-Rodriguez et al., 2016](#)). Skeletal tuberculosis may: 1) manifest vertebral body erosion, collapse, and ankylosis; 2) exhibit pleural periostitis and lytic lesions; 3) affect joints, usually the hip, knee, and wrist ([Ortner, 2003](#); [Roberts and Manchester, 2010](#)). Additionally, syphilitic osteomyelitis of the mandible has been reported although it is a rare condition ([Heslop, 1963](#)). Researchers should distinguish any additional lesions indicator of syphilis in the skeleton, such as *caries sicca*, from phosphorus necrosis of the jaw.

Osteopetrosis can generate osteomyelitis of the jaw, especially on the mandible ([Satomura et al., 2007](#); [Stark and Savarirayan, 2009](#); [García et al., 2013](#)). Osteopetrosis is a rare genetic disease resulting from a

defective function of osteoclasts leading to an increase in cortical bone reducing or even obliterating the medulla ([Ortner, 2003](#); [Stark and Savarirayan, 2009](#); [Satomura et al., 2007](#); [García et al., 2013](#)). Immature bone accumulation results in a fragile bone structure and the individuals become more prone to fractures ([García et al., 2013](#)). With time, the bones become sclerotic and opaque radiographically, affecting the skull, spine, appendicular bones, and pelvis ([Stark and Savarirayan, 2009](#); [García et al., 2013](#)). Osteopetrosis can be expressed between severe and mildest forms. Severe malignant forms are autosomal recessive happening in the first months of life and are life-threatening in the first years of life due to medullary suppression, anemia, and congestive heart failure ([Stark and Savarirayan, 2009](#); [García et al., 2013](#)). On autosomal recessive osteopetrosis individuals can show macrocephaly, frontal bossing, cloanal stenosis, hydrocephalus, and narrower nerve foramina ([Stark and Savarirayan, 2009](#)). Individuals will also show an impaired growth of long bones, dental defects, and develop severe dental caries ([Stark and Savarirayan, 2009](#)). Autosomal dominant osteopetrosis, considered the benign form, is usually diagnosed later in childhood or adolescence ([Stark and Savarirayan, 2009](#)). Individuals with autosomal dominant osteopetrosis may have anemia, frontal bossing, malocclusion of teeth, hip osteoarthritis, scoliosis, dense bands of sclerotic bone parallel to the vertebral endplate (“sandwich vertebrae”), and small cranial foramina, orbits and nasoethmoid complex ([Stark and Savarirayan, 2009](#); [García et al., 2013](#)).

Sickle-cell disease is another genetic illness that can result in osteomyelitis of the jaw ([Almeida and Roberts, 2005](#); [Araújo et al., 2014](#); [Chekroun et al., 2019](#)). Individuals with the sickle-cell disease show a higher frequency of dental caries and pulp necrosis associated with a decreased blood supply may cause osteomyelitis of the mandible ([Almeida and Roberts, 2005](#)). As a hemoglobin disorder - affecting African and Southern Mediterranean descendants - the red cells have a sickle shape which can potentially conglutinate causing vascular obstructions and a deficient transport of oxygen ([Ortner, 2003](#); [Araújo et al., 2014](#); [Chekroun et al., 2019](#)). Vascular obstruction affects mostly the medullary cavity and epiphysis, and it also affects the vertebral bone marrow which leads to the depression of the vertebral bodies resembling fish vertebrae ([Ortner, 2003](#); [Almeida and Roberts, 2005](#); [Roberts and Manchester, 2010](#)). Individuals with sickle cell disease show increased susceptibility to infections and necrosis especially in the femoral head ([Ortner, 2003](#); [Almeida and Roberts, 2005](#)). Other indicators sometimes displayed by individuals are: stress fractures; chronic arthritis; osteoporosis; delayed dental eruption; impaired bone growth; coarsening of the trabecular bone for vertebrae, ribs, scapula, sternum, and pelvis; enlargement of the marrow; thinning of the vertebral cortex; and thickened diplöe, orbital roof and zygoma ([Ortner, 2003](#); [Almeida and Roberts, 2005](#); [Roberts and Manchester, 2010](#); [Chekroun et al., 2019](#))

Osteomyelitis of the jaw may also occur with bacterial actinomyces along with other oral bacteria, possibly secondary to a dental

infection ([Lau et al., 2016](#); [Sezer et al., 2017](#); [Ayoade et al., 2018](#)). The diagnosis of Actinomycosis is not easy as it can affect almost any skeletal element in proximity to chronic infection and may mimic other diseases, such as neoplasms and fungi infections ([Ortner, 2003](#); [Lau et al., 2016](#); [Ayoade et al., 2018](#)). Even in a clinical setting, actinomycosis diagnosis is challenging, so, to aid in the diagnosis, a histological and bacteriological culture analysis is usually performed ([Lau et al., 2016](#); [Sezer et al., 2017](#)). Actinomycosis is an uncommon bacteriological infection but the most often affected elements are the face and neck ([Ortner, 2003](#)). Bone lesions by actinomycosis occur on the periosteal surface with: 1) increased number and size of the foramina; 2) superficial erosion with little sclerotic response; 3) uncommon formation of sequestered bone; 4) reactive subperiosteal bone formation ([Ortner, 2003](#)). Endemic fungal infections can also cause osteomyelitis of the mandible, although they are rare events ([Telles et al., 2017](#); [Albarillo et al., 2018](#)). Clinical diagnosis of fungi osteomyelitis involves tissue and fluid histopathological and culture analysis ([Telles et al., 2017](#)).

To aid in the diagnosis of phosphorus necrosis of the jaw from the diseases described above, attention must be paid to the archaeological and historical context the skeleton was exhumed from, i.e., from an industrial location where the factory of white phosphorus matches existed. Besides, the elemental analysis of dental calculus with a scanning electron microscope to trace phosphorus may also help in diagnosing phosphorus necrosis of the jaw ([Roberts et](#)

[al., 2016](#)). Hughes *et al.* (1962) noticed differences in the tartar of phosphorus factories workers which suggest possible changes in the chemistry of the saliva, due to prolonged exposure to white phosphorus. As a control measure calculus analysis from other individuals from the same context and a different archaeological site should be compared to results obtained for the individual who may have had phosphorus necrosis of the jaw (Roberts *et al.*, 2016). The analysis of calculus to analyze the level of phosphorus is advised instead of analyzing bone samples (Roberts *et al.*, 2016). Calculus can better preserve exogenous materials, while bone chemistry can be modified by diagenesis and due to soil contamination (Roberts *et al.*, 2016). Also, bone and teeth have calcium phosphate making it difficult to differentiate phosphorus occurring by exposure from the phosphorus that naturally occurs in bone and teeth, while calculus does not incorporate the natural phosphorus from the teeth (Roberts *et al.*, 2016).

## Conclusion

Phosphorus necrosis of the jaw was a debilitating industrial disease that affected workers exposed to white phosphorus fumes in poorly ventilated matches' factories. Phosphorus necrosis of the jaw commonly started with pain and could progress to the formation of an *involucrum* and necrotic bone. This industrial disease could cause facial disfigurement, social stigma, and even be fatal. No cure existed before the emergence of antibiotics, although doctors prescribed mouth-washes and performed jaw surgery to remove the necrotic bone. Health

legislation was implemented to improve factory conditions and curb the emergence of new cases of phosphorus necrosis of the jaw. Eventually, white phosphorus was prohibited on the matches production as earlier measurements did not eradicate the disease. Other pathological conditions, such as osteopetrosis, tuberculous osteomyelitis, and sickle-cell anemia can present similar indicators to phosphorus necrosis, therefore, besides an osteological and paleopathological analysis, the archaeological context and calculus analysis of phosphorus level may aid in the differential diagnosis. Few archaeological cases of phosphorus necrosis of the jaw have been reported in the literature, and thus this article brings awareness to this paleopathology especially for researchers studying industrial communities from the 19<sup>th</sup> and early 20<sup>th</sup> centuries.

## Acknowledgments

The author is most grateful to Jackson Ng for his support. I also thank the anonymous reviewer and editors for their helpful comments which improved the manuscript.

## References

- Albarillo, F. S.; Varma, G. T.; MacLeod, S. P. R. 2018. Mandibular blastomycosis: A case report and review of the literature. *GERMS*, 8(4): 207-213. DOI: 10.18683/germs.2018.1148
- Almeida, A.; Roberts, I. 2005. Bone involvement in sickle cell disease. *British Journal of Haematology*, 129(4): 482-490. DOI:10.1111/j.1365-2141.2005.05476.x
- Araújo, J. P.; Cadavid, A. M. H.; Lemos, C. A.; Trierveiler, M.; Alves, F. A. 2015. Bilateral mandibular osteomyelitis

- mimicking periapical cysts in a patient with sickle cell anemia. *Autopsy Case Reports*, 5(3): 55-60. DOI: 10.4322/acr.2015.013
- Arnold, A. J. 2004. "Ex Luce Lucellum"? Innovation, class interests and economic returns in the nineteenth century match trade. Exeter: Paper no. 04/06, University of Exeter.
- Ayoade, F.; Olayiwola, A.; Li, A. 2018. "Holes" in the Jaw—A Report of Two Cases of Periapical Actinomycosis. *Diseases*, 6 (79): 1-9. DOI: 10.3390/diseases6030079
- Borromeo, G. L.; Tsao, C. E.; Darby, I. B.; Ebeling, P. R. 2011. A review of the clinical implications of bisphosphonates. *Australian Dental Journal*, 56(1): 2–9. DOI: 10.1111/j.1834-7819.2010.01283.x
- Campillo, D. 2001. *Introducción a la paleopatología*. Barcelona, Bellaterra.
- Chekroun, M.; Chérifi, H.; Fournier, B.; Gaultier, F.; Sitbon, Y.; Côme Ferré, F.; Gogly, B. 2019. Oral manifestations of sickle cell disease. *British dental journal*, 226(1): 27-31. DOI: 10.1038/sj.bdj.2019.4
- Deardean, W. F. 1899. Fragilitas ossium amongst workers in Lucifer match factories. *The British Medical Journal*, 2: 270-271. DOI: 10.1136/bmj.2.2013.270-a
- Eldaya, R.; Eissa, O.; Herrmann, S.; Pham, J.; Calle, S.; Uribe, T. 2017. Mandibular lesions: a practical approach for diagnosis based on multimodality imaging findings. *Contemporary Diagnostic Radiology*, 40(6): 1-7. DOI:10.1097/01.CDR.0000513197.01378.d8
- Evans, R. D. 1933. Radium poisoning: a review of present knowledge. *American Journal of Public Health and The Nation's Health*, 23(10): 1017-1023.
- Fresco, R. E.; Fernández, N. P.; Urizar, J. M. A. 2006. Bisphosphonates and Oral Pathology II. Osteonecrosis of the jaws: Review of the literature before 2005. *Medicina Oral, Patología Oral y Cirugía Bucal*, 11(6): E456-461.
- García, C. M.; García, M. A. P.; García, R. G.; Gil, F. M. 2013. Osteomyelitis of the mandible in a patient with osteopetrosis: case report and review of the literature. *Journal of Maxillofacial and Oral Surgery*, 12(1): 94–99. DOI: 10.1007/s12663-011-0196-y
- Gavrić, M.; Antić, S.; Jelovac, D. B.; Zarev, A. I.; Petrović, M. B.; Golubović, M.; Antunović, M. 2014. Osteonecrosis of the jaw as a serious adverse effect of bisphosphonate therapy and its indistinct etiopathogenesis. *Vojnosanit Pregled*, 71(8): 772–776. DOI: 10.2298/VSP121211025G
- Gudmundsson, T.; Torkov P.; Thygesen, T. H. 2017. Diagnosis and treatment of osteomyelitis of the jaw: a systematic review (2002-2015) of the literature. *Journal of Dentistry & Oral Disorders*, 3(4): 1-11. DOI:10.26420/jdentoraldisord.2017.1066
- Gunderman, R. B.; Gonda, A. S. 2015. Radium girls. *Radiology*, 274:314–318. DOI: 10.1148/radiol.14141352
- Harrison, B. 1996. *Not only the 'dangerous trades': women's work and health in Britain, 1880–1914*. London, UK Taylor & Francis Ltd.
- Hellstein, J. W.; Marek, C. L. 2005. Bisphosphonate osteochemonecrosis (bis-phossy jaw): is this phossy jaw of the 21st century?. *Journal of Oral Maxillofacial Surgery*, 63(5):682-689. DOI:10.1016/j.joms.2005.01.010
- Heslop, I. H. 1963. Syphilitic osteomyelitis of the mandible. *British Journal of Oral Surgery*, 6(1): 59-63. doi: 10.1016/s0007-117x(68)80027-7
- Hinshaw, W. B.; Quinn, L. D. 2005. Recognition of the causative agent of "phossy jaw" and "fragile femur" in fumes arising from white phosphorus. *Phosphorus, Sulfur, and Silicon and the Related Elements*, 190(12): 2082-2093. DOI: 10.1080/10426507.2015.1071818
- Hughes, J. P. W.; Baron, R.; Buckland, D. H.; Cooke, M. A.; Craig, J. D.; Duffield, D. P.; Grosart, A. W.; Parkes, P. W. J.; Porter, A. 1962. Phosphorus necrosis of the jaw: a present-day study. *Occupational and Environmental Medicine*, 19(2): 83-99. DOI: 10.1136/oem.19.2.83
- Jacobsen, C.; Zemann, W.; Obwegeser, J. A.; Grätz, K. W.; Metzler, P. 2014. The phosphorous necrosis of the jaws and what can we learn from the past: a comparison of "phossy" and "bisphossy" jaw. *Journal of Oral and Maxillofacial Surgery*, 18(1): 31-37. DOI 10.1007/s10006-012-0376-z
- Kamath, A. T.; Radhakrishnan, R.; Bhagania, M.; Mohan, A. 2015. Tuberculous Osteomyelitis of the Mandible. *Journal of Oral and Maxillofacial*, 14(Suppl 1): 200-202. DOI: 10.1007/s12663-012-0414-2
- Lau, L.; Darraj, M.; Keynan, Y. 2016. Mandibular Actinomyces osteomyelitis mimicking osteosarcoma. *JMM Case Reports*, 3(6): 1-3. DOI: 10.1099/jmmcr.0.005073
- Lehman, E. 2017. Match-making in Britain from 1827 to 1910: The Dangers of White Phosphorus in Lucifer Match Production. *University of Saskatchewan Undergraduate Research Journal*, 3(2): 1-10. DOI: https://doi.org/10.32396/usurj.v3i2.231
- Martland, H.S. 1931. The Occurrence of malignancy in radioactive persons. *The American Journal of Cancer*, 15(4): 2435-2516. DOI: 10.1158/ajc.1931.2435
- Marx, R. E. 2008. Uncovering the cause of "phossy jaw" circa 1858 to 1906: oral and maxillofacial surgery closed case files—case closed. *Journal of Oral and Maxillofacial*, 66(11):

- 2356–2363. DOI: <https://doi.org/10.1016/j.joms.2007.11.006>
- Myers, M. L.; McGlothlin, J. D. 1996. Matchmakers' "Phossy Jaw" Eradicated Myers, *American Industrial Hygiene Association Journal* 57(4): 330-332.
- Neha; Mahajan, S. 2018. An Invasive Squamous Cell Carcinoma of Mandible Presenting as Chronic Osteomyelitis: A Case Report. *Acta Scientific Dental Sciences*, 2(5): 81-83.
- Ortner, D. J. 2003. *Identification of pathological conditions in human skeletal remains*. Washington, Smithsonian Institution Press.
- Phal, P. M.; Myall, R. W. T.; Assael, L. A.; Weissman, J. L. 2007. Imaging findings of bisphosphonate-associated osteonecrosis of the jaws. *American Journal of Neuroradiology*, 28(6):1139–45. DOI 10.3174/ajnr.A0518
- Pollock, R. A.; Brown, Jr., T. W.; Rubin, D. M. 2015. "Phossy jaw" and "bis-phossy jaw" of the 19<sup>th</sup> and the 21<sup>st</sup> centuries: The diuturnity of John Walker and the friction match. *Craniofacial Trauma & Reconstruction*, 8(3): 262-270. DOI: 10.1055/s-0035-1558452
- Roberts, C. A.; Manchester, K. 2010. *The Archaeology of disease*. Stroud, Sutton Publishing.
- Roberts, C. A.; Caffell, A.; Filippek-Ogden, K. L.; Gowland, R.; Jakob, T. 2016. 'Til poison phosphorous brought them death': A potentially occupationally-related disease in a post-medieval skeleton from north-east England. *International Journal of Paleopathology*, 13: 39-48. DOI: 10.1016/j.ijpp.2015.12.001
- Robinson, N. A.; Yeo, J. F. 2004. Bisphosphonates: a word of caution. *Annals of the Academy of Medicine, Singapore*, 33(4): 48S-49S.
- Satomura, K.; Kon, M.; Tokuyama, R.; Tomonari, M.; Takechi, M.; Yuasa, T.; Tatehara, S.; Nagayama, M. 2007. Osteopetrosis complicated by osteomyelitis of the mandible: a case report including characterization of the osteopetrotic bone. *International Journal of Oral and Maxillofacial* 36(1): 86–93. DOI: 10.1016/j.ijom.2006.06.009
- Sezer, B.; Akdeniz, B. G.; Günbay, S.; Hilmioglu-Polat, S.; Başdemir, G. 2017. Actinomycosis osteomyelitis of the jaws: Report of four cases and a review of the literature. *Journal of Dental Sciences*, 12(3): 301-307. DOI: 10.1016/j.jds.2013.02.031
- Stark, Z.; Savarirayan, R. 2009. Osteopetrosis. *Orphanet Journal of Rare Diseases*, 4(5): 1-12. DOI: 10.1186/1750-1172-4-5
- Telles, D. R.; Karki, N.; Marshall, M. W. 2017. Oral fungal infections: Diagnosis and management. *Dental Clinics of North America*, 61(2): 319–349. DOI: 10.1016/j.cden.2016.12.004
- Tellez-Rodriguez, J.; Lopez-Fernandez, R.; Rodriguez-Jurado, R.; Moreno-Sandoval, H. N.; Martinez-Perez, F.; Gonzalez-Barrios, J. A. 2016. Mycobacterium tuberculosis as a cause of mandibular osteomyelitis in a young woman: a case report. *Journal of Medical Case Reports*, 10(366): 1-6. DOI: 10.1186/s13256-016-1118-x
- Valoriani, S.; Eliopoulos, C.; Irish, J.D.; Borrini, M. 2020. Health and safety issues in the Victorian workplace: An example of mandibular phosphorus necrosis from Gloucester, UK. *International Journal of Osteoarchaeology*, 30(1): 73-79. DOI: 10.1002/oa.2833
- von Bibra, E.; Geist, L. 1848. Diseases caused by the vapours of phosphorus. *The British and foreign medico-chirurgical review*, 1(2): 446-461.
- Ward, E. F. 1926. Phosphorus necrosis in the manufacture of fireworks and in the preparation of phosphorus. *Bulletin of the US Bureau of Labor Statistics*, (405): 1-44.
- Wood, J.R. 1857. *Removal of the entire lower jaw*. New York, s.n.
- Wright, W. C. 1846-1847. Case of salivation and diseased jaw from the fumes of phosphorus. *The Medical Times: A Journal of English and Foreign Medicine and Miscellany of Medical Affairs*, 15: 224-225.